

Preliminary results in cochlear implant surgery without antromastoidectomy and with atraumatic electrode insertion: the endomeatal approach

Victor Slavutsky · Luis Nicenboim

Received: 21 December 2007 / Accepted: 3 July 2008
© Springer-Verlag 2008

Abstract A surgical approach using the external auditory canal and the round window as a natural access pathway for cochlear implant positioning, the endomeatal approach, is described. This approach avoids performing an antromastoidectomy, the subsequent posterior tympanotomy and the promontorial cochleostomy. The endomeatal approach also allows an optimal insertion plane for electrode array atraumatic insertion through the round window. The technique was developed and practiced in 35 fresh temporal bones and then it was applied in ten patients. This surgery has an endomeatal first stage, which begins with a stapedectomy-like tympanomeatal flap. This flap allows an easy access to scala tympani via round window niche. The internal part of a groove is drilled on the posterior wall of the EAC. The groove is parallel to the EAC axis and starts in its inner border. Once the endomeatal stage is completed, a standard retroauricular approach is performed, in order to make the receptor–stimulator well and to complete the groove externally, until it connects the middle ear with the external mastoid surface. A flat second well is drilled in front of the first one to lodge the remaining electrode lead. In small children this well is deepened. The electrode array is introduced in the scala tympani through the RW and located into the

groove. The electrode is covered and fixed inside the groove with bone paté. The extra length of the electrode lead is located in the second well and the receptor–stimulator is fixed in its well. The ground electrode is placed under the periosteum, the retroauricular incision is sutured, the tympanomeatal flap is restored and a dressing is placed into the EAC. Surgical time was significantly shorter than in standard approach. There were neither surgical nor healing complications. Electrode insertion was easy and complete and functional results were adequate. The goal of this approach is to avoid antromastoidectomy and posterior tympanotomy, which are replaced by the EAC groove. It is faster and safer, eliminating the risk of facial nerve injury. It also allows a better access to the round window, with a less traumatic electrode insertion, suitable for “soft surgery” performing. It may advantageously replace the classical transmastoid approach.

Keywords Cochlear implant · External auditory canal · Endomeatal approach · Tympanomeatal flap · Round window · Electrode array · Facial nerve · Scala tympani

Introduction

The usual surgical technique for cochlear implantation involves an antromastoidectomy and a posterior tympanotomy (PT) through the facial recess [1]. In this paper a new technique is presented that uses a direct approach via the external auditory canal (EAC). The endomeatal approach (EMA) was first developed in the temporal bone lab and after that, surgeries were performed. The data obtained in bone dissection, the surgical technique and surgery results are presented here.

V. Slavutsky
Ent Clinic, Barcelona, Spain

L. Nicenboim
Ear Institute and Universidad Abierta Interamericana,
Rosario, Argentina

V. Slavutsky (✉)
Plaza Ayuntamiento, 2 2ª1ª, 08870 SITGES, Barcelona, Spain
e-mail: victor.slavutsky@gmail.com

Temporal bone dissection: materials and methods

Thirty five fresh temporal bones were dissected in order to find the optimal insertion plane through the round window (RW) to slide the electrode array (EA) into the scala tympani (ST) with less cochlear neuronal content injury.

The position and size for an EAC groove destined to EA lodging are also determined.

Dissection findings and results

Optimal insertion plane

Although there are variations among specimens [2], dissection shows always a quite similar size, spatial configuration and position of cochlear bone and its contents. This is true for the 35 specimens studied. This is an expected finding, because it is known that inner ear shape and size is characteristic of each mammalian species and remains almost unchanged from birth to death. These findings are extensive to ST. ST starts its basal turn immediately after RW, describing from its onset a spiral curve centered in the modiolus. Therefore, in its way to the cochlear apex the ST longitudinal axis is changing its direction continuously, going initially downward and forward, after a few millimeters takes a horizontal, to the front and inward direction and after that an inward and upward direction. The RW and its membrane are like an oblique base for the ST cylinder, with its visible face looking outward and backward.

Therefore, to facilitate EA introduction by the RW and avoid damage to inner ear structures the EA must be slid inside ST following a downward–forward direction, along the crista fenestra (hook shaped structure corresponding to RW anteroinferior edge) inner face (Figs. 1, 3). This insertion line follows the longitudinal axis of ST, allowing the EA to gently curve over the external ST wall. The bone dissection work establishes that the insertion line is on an imaginary plane, which passes superiorly between the posterior rim of the oval window and the pyramidal process, and inferiorly by the internal side of the RW hook (Figs. 1, 2). The RW size and shape have some degree of variability among specimens, as it has been reported [3]. Despite this variability, when the insertion plane was followed it was possible to insert an EA (we perform the trials with a dummy Nucleus Contour Advance EA) without drilling RW margins.

The bony overhang that contributes to form the RW niche has variable sizes in the different specimens, sometimes covering the RW partially and others totally. The overhang must have a complete drill-out in order to unblock EA introduction [3].

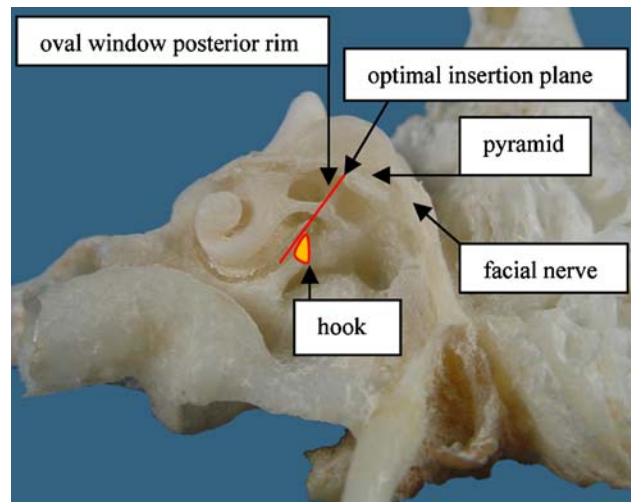


Fig. 1 Optimal insertion plane (red line). Dissected left temporal bone, courtesy of Rodrigo Posada, MD

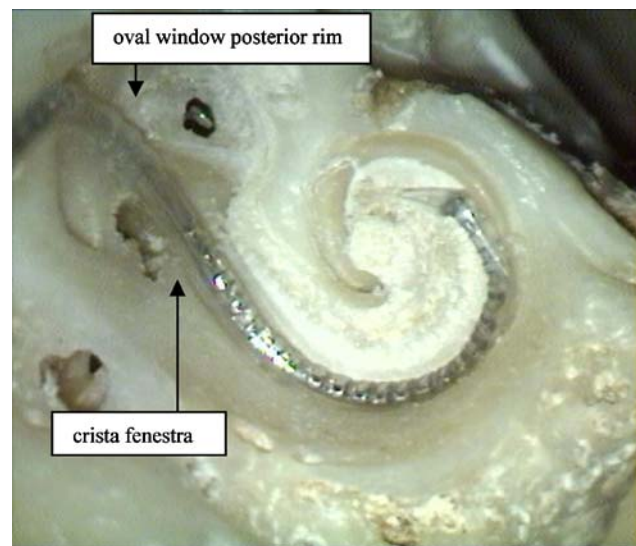


Fig. 2 Landmarks of the EMA optimal insertion plane with the EA inserted. Cochlea's inner view

The groove

EMA requires making a bony EAC groove for electrode lead (EL) lodging, in order to avoid contact between the skin and the EL that could lead to its extrusion.

A safe anatomic area to perform the groove with no risk for adjacent structures like facial nerve, chorda tympani, eardrum and ossicular chain were studied and finally established with these landmarks: the incus and pyramidal process in the inner EAC side, and the outer border of tympano-squamous suture in the outer side. This groove placement is also on line with the axis of the more basal segment of ST, so the EL does not suffer any degree of bending after it is finally positioned in the ST. From the

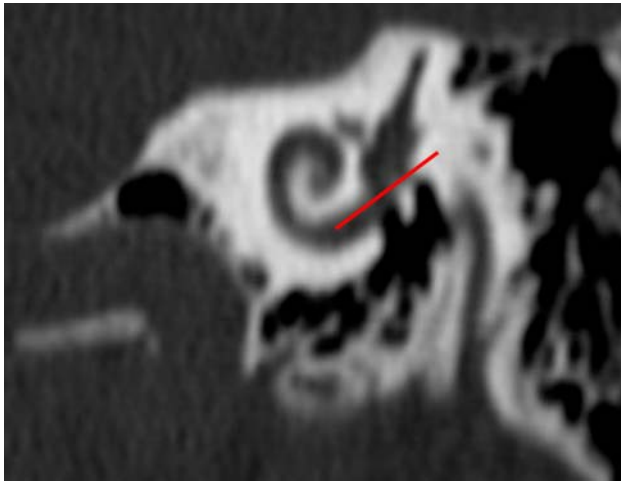


Fig. 3 Red line EMA insertion plane. Oblique CT scan, left ear (Courtesy of Instituto Gamma, Rosario)

pyramidal process in up, there is enough room to drill a groove with a 0.5 mm cutting burr. An overhang is left in the superior groove's edge, in order to retain the electrode lead and avoid its contact with the EAC skin, therefore preventing extrusion (Figs. 4, 5). 1 mm wide and 2 mm depth is enough to cross the fallopian canal at a safe distance and lodge the EL. The pyramid level is the best place for the following reasons:

- a safe distance to FN even in infants;
- good direct control of fallopian canal, visible at oval window;
- good position for electrode insertion in the plane described before;

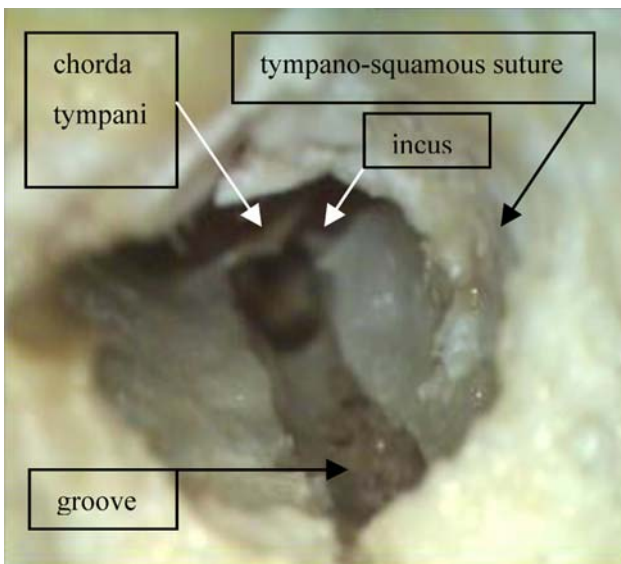


Fig. 4 Left temporal bone dissection with the groove landmarks

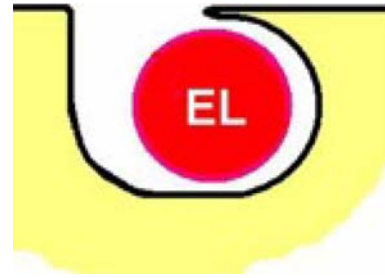

Fig. 5 Schematic groove's cut, showing the overhang that retains EL

EL does not cross over the incus long process in its way to the RW.

Cochlear implant surgery: materials and methods

Ten patients were implanted using the EMA. The age, sex, deafness etiology, technique used, CI model and postoperative follow-up period are detailed in table 1.

Surgical technique

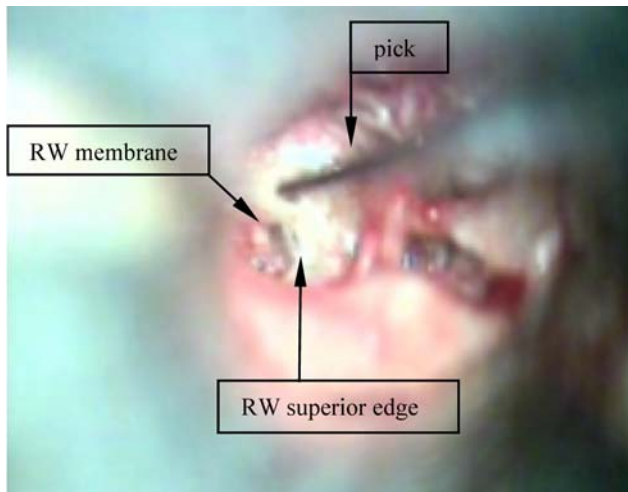
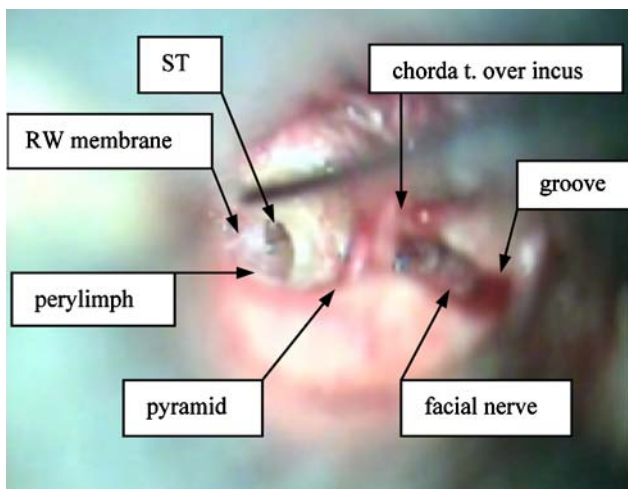
First stage: endomeatal

Anterior tympanotomy and exposure of the RW membrane

This stage is aided with an autostatic ear speculum. It starts with an endomeatal stapedectomy-like but a few millimeters more external-skin incision, in the posterior wall of the bony EAC. The skin is carefully elevated and the tympanic annulus is desinserted. The tympanomeatal flap is driven forward over the anterior eardrum quadrants, respecting the malleolar eardrum insertion. At this moment the RW and promontory are visualized. The tympanic bone margin must be lowered with a curette or diamond burr in order to complete the RW visualization-if necessary and to expose the chorda tympani, the pyramidal process, the incus long process, the stapes, the oval window and the fallopian canal (Figs. 6, 7). With a Skeeter microdrill the overhang bone projection that protects the RW is totally removed until complete RW membrane exposition. The membrane is preserved at this stage in order to prevent perilymph lost and bone dust entrance into ST. Taking as reference the location of the RW, the pyramidal process, and the incus in the inner border of the EAC, and the tympano-squamous suture in the outer border, a 1 mm width and 2 mm depth groove is performed in the EAC posterior wall from inside to outside, in the EAC axis direction, with a Skeeter microdrill [Fig. 4]. As stated in bone lab section, an overhang is left in order to retain EL. The groove starts approximately at the

Table 1 Relation of implanted patients

Patient	Age	Sex	Deafness etiology	Technique	CI	Follow-up (month)
1	71	M	Unknown prog.	EMA	N. 24 K	18
2	64	F	Unknown prog.	EMA	N. 24 Contour	18
3	22	F	Genetic	EMA	N. Freedom	14
4	13	F	Genetic	EMA	N. Freedom	10
5	16	F	Rubeola	EMA	N. 24 K	7
6	74	F	Otosclerosis	EMA	N. 24 K	7
7	18 month	F	Prematurity anoxia	EMAC	C. Hifocus JE	6
8	45	F	Chronic OM	EMA	C. Hifocus JE	6
9	19 month	M	Genetic	EMAC	N. Freedom	3
10	23	M	Meningitis	EMA	N. Freedom	3

**Fig. 6** Starting detachment of RW membrane from its superior edge**Fig. 7** EMA RW cochleostomy. Anatomical relations

pyramidal process level and extends laterally up to the endomeatal skin incision external lip.

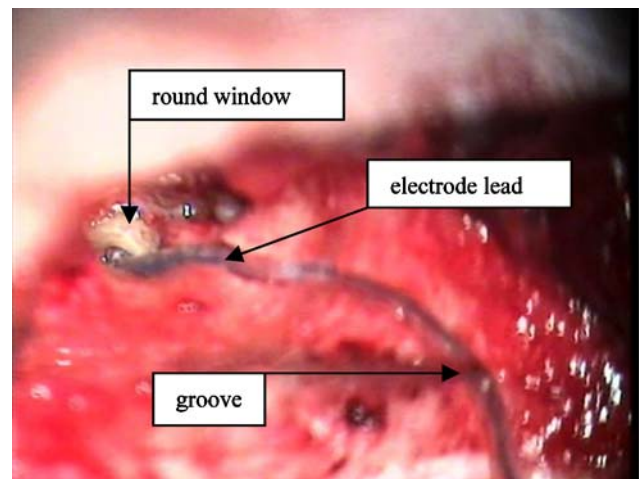
In order to avoid CT damage, in some cases it is necessary to separate it from the tympanic ring. The bone dust is

carefully cleaned with suction-irrigation. The TC and the tympanomeatal flap are protected with Gelfoam.

Second stage: retroauricular

Groove lateral segment. Receiver-stimulator well and second well for the remaining EL

A retroauricular skin incision with a small postero-superior extension is performed [4] and the muscle-aponeurotic plane is dissected one centimeter in both incision lips. The muscle is incised to the bone and the periosteum is detached creating in a posterior manner a pocket for the receiver-stimulator, and discovering in an anterior manner the mastoid bony surface up to the EAC. The dissection is continued into the EAC until the endomeatal skin incision external lip is detached from the bone, and the internal part of the bony EAC is visible, with the groove carved in the first stage. Then the groove drilling is resumed and prolonged up to the external mastoid surface (Fig. 8). The

**Fig. 8** The EL inside the groove. Deep insertion through the RW. EMA second stage

receiver–stimulator (RS) well is drilled and a 2 cm diameter and 3 mm depth flat second well is performed in front of the first one. This second well is connected forward to the groove and backward to the RS well. The TC Gelfoam protection is removed, and the RW membrane is incised with a pick from its superior edge to the antero-inferior edge, taking care with its posterior aspect that is in close relation with the spiral lamina (Fig. 6).

The RS is placed in the pocket and the proximal portion of the electrode array is introduced through the EAC up to the TC.

The tympanotomy is wide open, with the tympanomeatal flap driven forward and protected with Gelfoam. It results in a clear RW exposure, since the posterior EAC skin and the eardrum do not bother any surgical maneuver.

Optimal plane of electrode insertion

It is necessary to consider that the EMA allows the EA to come from a more superior and anterior position, without being limited by the posterior wall as it happens in the PT approach.

The insertion is made in an up to down, back to front direction, from the EAC postero-superior part up to the superior edge of the round window. That results in an insertion angle approximately 30° more anterior, and also 15° more superior (Fig. 9) compared with the PT insertion angle (Fig. 10). That explains why EMA avoids to crush modiolar wall, spiral lamina and/or basilar membrane as Roland et al. [3] refer, coming from a more vertical position and with enough space in the EAC to lead the EA to slide over the ST curved outer wall, in a more inferior position, farther from the basilar membrane and spiral lamina and running away from the inner wall. (Figs. 1, 2, 3).

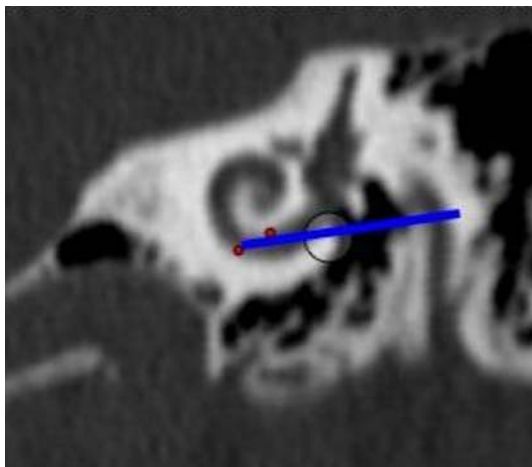


Fig. 9 PT insertion plane with crash points in red. The circle represents the cochleostomy

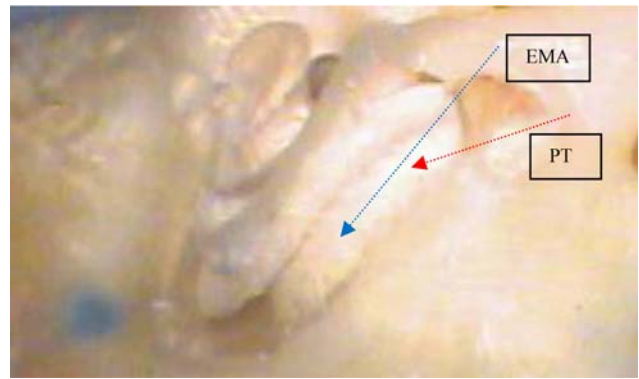


Fig. 10 Angle of insertion corresponding to PT and EMA

Once the insertion is done, the EL is gently introduced inside the groove (Fig. 8) and kept in place carefully filling the groove with bone paté [5] (Figs. 11, 13).

The RS is sutured in its bony well to the surrounding periosteum. The remaining EL is located inside the flat second well that has been performed with undercut edges to prevent extrusion. The ground electrode is located under the periosteum, in contact with the temporal bone, and the retroauricular incision is sutured by planes.

Third stage: endomeatal

RW seal: telemetry measurements. Tympanomeatal flap restoring

The RW is sealed with connective tissue (Fig. 11). The telemetry and electric stapedial reflex measures are carried out, the tympanomeatal flap is restored and the skin adapted over the groove. The final stage ends by carefully dressing

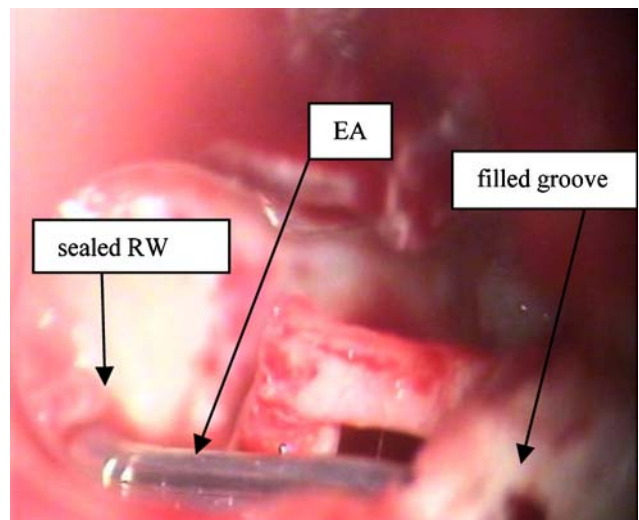


Fig. 11 Electrode array with sealed RW and filled groove. EMA third stage

with Gelfoam the EAC internal segment and with gauze in its external part. The retroauricular incision is dressed as usual.

EMA modified technique for small children surgery (EMAC)

In small children the anterior well is replaced by a deeper mastoid cavity with the posterior canal wall thinned. This cavity is limited in depth to the EAC's external 2/3 level and it is not necessary to open the antrum [18]. The external groove's segment is converted in a narrow open cleft, extended from the external wall's edge to the cavity's bottom. The cleft allows EA introduction into the bottom of the cavity, limiting its course inside a groove to an extent of 2 or 3 mm. The cleft and the short groove are obturated with bone paté. The groove is limited to the EAC's internal third, therefore avoiding EA displacement or stretching by canal wall growing (Fig. 12). In EMAC the final EL's position does not change too much from the surgery practiced through the facial recess, therefore we can consider EMAC as stable with growing as PT approach.

Postoperative care

EAC dressing and retroauricular suture are removed between the seventh to tenth postoperative day. The patient is controlled weekly during a month. CI is activated at the fourth week after surgery.

Surgical results

Surgery was fast and easy, without complications in the ten cases. The EA insertion was smooth and easy in all cases.

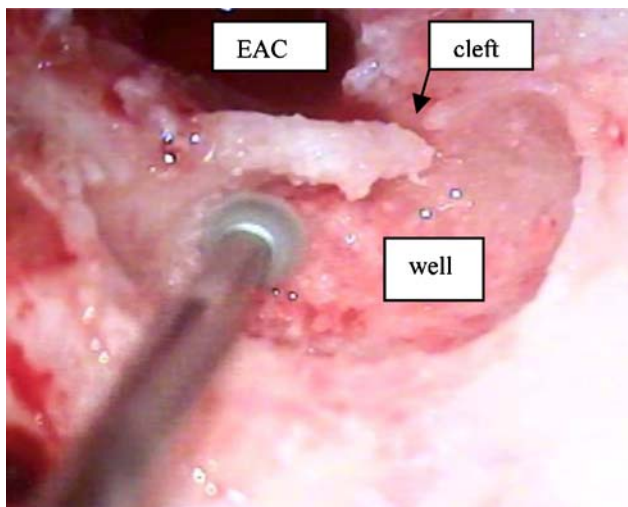


Fig. 12 Children's anterior well. Left ear

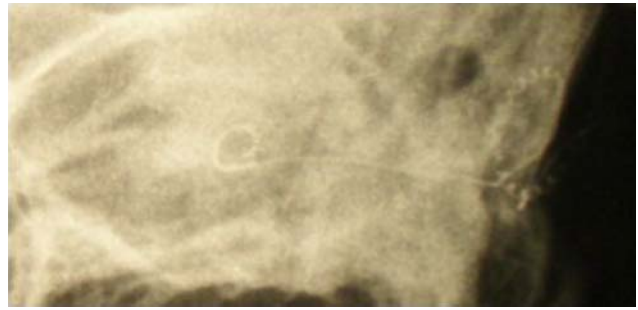

Fig. 13 Rx showing EA inside cochlea and EL along EAC

EAC skin healing was also without complications, and completed in 7–10 days. The posterior incision healed like expected in conventional CI surgery. After a 3–18 months follow-up there is no electrode extrusion and EAC skin and shape look normal in the ten patients.

Functional results

The ten devices are working properly and results are according to what was expected in all patients.

Discussion

The success of cochlear implant surgery is mainly conditioned by right positioning of the electrode array inside the cochlea through RW or a promontorial cochleostomy [6]. Although RW and promontory are wide and easily visualized via direct EMA, the usual technique of implantation involves a mastoidectomy and a PT. The PT through the facial recess must be done carefully and preferably with facial nerve (FN) monitoring to avoid FN injury. It is often impossible to preserve the CT because it is injured by the drill or has to be sacrificed in order to obtain enough room for RW, promontory visualization and electrode introduction [7]. The incidence of FN lesions following CI surgery has been reported to be in the order of 1% [8]. The nerve damage may be related to direct injury or by heat produced by rotating instruments.

This approach also allows for a faster and better access to the scala tympani, either by the RW or a cochleostomy. The groove making does not represent any compromise to FN, because it is placed in the posterior EAC wall distant to the nerve, in a position easily controlled by the visualization of the fallopian canal over the oval window. The chorda tympani is also visualized and easily preserved. In a standard approach the electrode array is inside the mastoid cavity and a middle ear infection could be transmitted to the implant, leading to biofilm formation in the implant silicone cover [9]. Another complication is a cholesteatoma

due to skin penetration in the mastoid cavity by a hole left in the posterior EAC wall.

These complications are avoided in EMA, because only a small segment of the electrode array is in the middle ear space and there is no mastoid cavity.

The main objection about EMA is the possibility of electrode array extrusion through EAC thin skin. This complication was described in previous attempts of EAC approaches [10, 11].

Hausler in 2002 presented a “pericanal electrode insertion technique” [12], with a bony groove in the EAC similar to the one described herein. He avoids the electrode extrusion by fixing it inside the groove with special cement, the *glass ionomer cement*. There are several differences between Hausler technique and ours. He approaches the TC by the retroauricular incision, creating a long skin flap difficult to manage, that could lead to EAC skin lesions and/or tympanic membrane perforations, as he refers in six cases. The long flap is also difficult to hold forward resulting in less working space. The endomeatal incision and the use of an autostatic speculum maximize the working space [13] facilitating the making of the groove, the opening of scala tympani and the positioning of the EA. The risk of skin laceration and tympanic membrane perforation is very low for experienced surgeons used to perform stapedectomies and other endoaural procedures. Once repositioned, the flap heals completely in about a week. The bone paté [5] are enough to maintain the electrode inside the groove and to avoid its contact with the skin. The cement produces a rigid fixation that could be a problem when implanting children, leading to electrode rupture or extrusion as the child grows.

Other surgical techniques without mastoidectomy are those developed by Kiratsidis [14] and Kronenberg [15]. Both surgeons drill blind tunnels in the mastoid bone to enter the tympanic cavity. The advantage of EMA is that the groove is drilled under permanent visual control.

Another EMA advantage is a better electrode insertion angle than facial recess approach. As we have described in dissection results, basal spira starts downward at RW level. The PT is a small window that let us see the RW and the promontory only from the back. For EA positioning inside the cochlea, it must be driven forward horizontally, forcing to drill the RW hook or to perform a cochleostomy anterior and inferior to RW in order to catch the horizontal segment of the spira [16]. In EMA, EA is introduced in TC in front of EAC posterior wall, instead of coming from the back, between the close limits of PT. Therefore EMA allows us to introduce the electrode from a superior position, following the plane described in dissection results and surgical technique. This insertion line matches scala tympani initial direction and following it avoids crashing the electrode against the spiral lamina and facilitates its introduction. The electrode follows all the time the ST longitudinal axis,

which is spirally curved from its beginning in the RW. The insertion is smooth and there is not necessary to drill RW margins in most of the cases. In some cases, anatomical variabilities force us to drill what Roland et al. [3] named “RW margin cochleostomy”. The better angle of insertion allows in these cases less drilling than in PT approach. The need and amount of drilling also depends on electrode design.

The EA follows the external ST wall, thus avoiding damage the cochlear neural content. This is actually a “soft surgery” [17], suitable for hearing conservation in partially deafened patients, with appropriate designed electrodes.

This approach also avoids false pathways and increases stimulation of the neuronal population, by placing the basal electrodes at the onset of the scala tympani.

To obtain an adequate RW insertion with PT approach Roland et al. [3] refer: “... occasionally requires sacrifice of the chorda tympani to achieve adequate exposure. Removal of the incus buttress may be necessary to allow for the appropriate angle of insertion”. According with Skarzynski et al. [13], in many cases an anterior tympanotomy may be necessary for better RW visualization while performing soft surgery via PT. Goycoolea et al. [14] also perform anterior tympanotomy for better visualization and instrumentation during standard PT approach. Anterior tympanotomy is inherent to EMA, therefore making unnecessary to perform both tympanotomies.

Conclusions

The goal of this approach is to avoid antromastoidectomy, PT and promontorial cochleostomy, which are replaced by the EAC groove and the RW insertion. It is a faster and easier technique, which requires less bony demolition, and completely avoids the risk of FN injury. The CT is also better preserved and the RW direct endomeatal visualization facilitates the electrode array introduction into the scala tympani. EMA may advantageously replace the retroauricular approach in patients with normal cochleae. Also, it may be adapted for use in malformed or ossified cochleae [13]. EMA modified technique for children allows its use at any age.

EMA reduces surgical time with same functional results.

Acknowledgments We gratefully thank Rodrigo Posada Trujillo, MD for his superb dissection work and his anatomical explanations.

References

1. Clark GM, Pyman BC, Bayley QR (1979) The surgery for multiple electrode cochlear implantations. *J Laryngol Otol* 93:215–228
2. Escudé B, James C, Deguine O, Cochard N, Eter E, Fraysse B (2006) The size of the cochlea and predictions of insertion depth

- angles for cochlear implant electrodes. *Audiol Neurotol* 11(Suppl 1):27–33
3. Roland PS, Wright CG, Isaacson B (2007) Cochlear implant electrode insertion: the round window revisited. *Laryngoscope* 117(8):1397–1402
 4. Telian SA, El-Kashlan HK, Arts HA (1999) Minimizing wound complications in cochlear implant surgery. *Am J Otol* 20(3):331–334
 5. Gstoettner WK, Hamzavi J, Baumgartner WD, Czerny CC (2000) Fixation of the electrode array with bone paté in cochlear implant surgery. *Acta Otolaryngol* 120(3):369–374
 6. Li PM, Wang H, Northrop C, Merchant SN, Nadol JB Jr (2007) Anatomy of the round window and hook region of the cochlea with implications for cochlear implantation and other endocochlear surgical procedures. *Otol Neurotol* 28(5):641–648
 7. Hamamoto M, Murakami G, Kataura A (2000) Topographical relationships among the facial nerve, chorda tympani nerve and round window with special reference to the approach route for cochlear implant surgery. *Clin Anat* 13(4):251–256
 8. Fayad JN, Wanna GB, Micheletto JN, Parisier SC (2003) Facial nerve paralysis following cochlear implant surgery. *Laryngoscope* 113(8):1344–1346
 9. Vlastarakos PV, Nikolopoulos TP, Maragoudakis P, Tzagaroulakis A, Ferekidis E (2007) Biofilms in ear, nose, and throat infections: how important are they? *Laryngoscope* 117(4):668–673
 10. Schindler RA (1985) Surgical consideration for multichannel cochlear implants. In: Schindler RA, Merzenich MM (eds) *Cochlear implants*. Raven Press, New York, pp 417–420
 11. Banfai P, Kubic S, Hortmann G (1983) Out extra-scalar operating method of cochlear implantation. Experience with 46 cases. *Acta Otolaryngol Suppl (Stockh)* 411:9–12
 12. Hausler R (2002) Cochlear implantation without mastoidectomy: the pericanal electrode insertion technique. *Acta Otolaryngol* 122:715–719
 13. Goycoolea MV, Ribalta GL (2003) Exploratory tympanotomy: an integral part of cochlear implantation. *Acta Otolaryngol* 123(2):223–226
 14. Kiratzidis T (2000) Veria operation: cochlear implantation without a mastoidectomy and a posterior tympanotomy. *Adv Otorhinolaryngol* 57:127–130
 15. Kronenberg J, Migirov L, Dagan T (2001) Suprameatal approach: new surgical approach for cochlear implantation. *J Laryngol Otol* 115:283–285
 16. Briggs RJ, Tykcinsky M, Stidham K, Robertson JB (2005) Cochleostomy site: implications for electrode placement and hearing preservation. *Acta Otolaryngol* 125(8):870–876
 17. Cohen NL (1997) Cochlear implant soft surgery: fact or fantasy? *Otolaryngol Head Neck Surg* 117(3):214–216
 18. Doyle WJ (2007) The mastoid as a functional rate-limiter of middle ear pressure change. *Int J Pediatr Otorhinolaryngol* 71(3):393–402